

---

## CLINICAL REPORT

---

# The Use of Stellate Ganglion Block in the Treatment of Panic/Anxiety Symptoms with Combat-Related Post-Traumatic Stress Disorder; Preliminary Results of Long-Term Follow-Up: A Case Series

---

Sean W. Mulvaney, MD\*<sup>\*</sup>; Brian McLean, MD<sup>†</sup>; Jason de Leeuw, PsyD, ABPP<sup>‡</sup>  
*\*Consortium for Health and Military Performance, Uniformed Services University, Bethesda, Maryland; <sup>†</sup>Department of Interventional Pain Management and Anesthesia, Tripler Army Medical Center, Honolulu, Hawaii; <sup>‡</sup>Kimbrough Ambulatory Care Center, Fort Meade, Maryland, U.S.A.*

### ■ Abstract

**Objective:** Report the successful use of stellate ganglion blocks (SGBs) in two patients experiencing symptoms of post-traumatic stress disorder (PTSD).

**Background:** Successful treatment of PTSD with SGB has been reported previously. A similar protocol was employed at Walter Reed Army Medical Center to treat two soldiers with chronic, combat-related PTSD.

**Methods:** Both patients received a SGB on the right side at C6 level. The patients' PTSD symptoms were evaluated using

the Post-traumatic Stress Disorder Checklist (PCL). The PCL was administered the day prior to treatment, to establish a baseline, and the day after treatment. The PCL was also utilized during follow-up visits to quantify the patient's symptomatology. The SGB was administered by an anesthesiologist and the psychometric tests administered by a psychologist.

**Results:** Both patients experienced immediate, significant and durable relief as measured by the PCL (score minimum 17, maximum 85). In both instances, the pre-treatment score suggested a PTSD diagnosis whereas the post-treatment scores did not. One patient requested repeat treatment after 3 months, and the post-treatment score remained below the PTSD cutoff after 7 additional months of follow-up. Both patients discontinued all antidepressant and antipsychotic medications while maintaining their improved PCL score.

**Conclusion:** Selective blockade of the right stellate ganglion at C6 level is a safe and minimally invasive procedure that may provide durable relief from PTSD symptoms, allowing the safe discontinuation of psychiatric medications. ■

Address correspondence and reprint requests to: Sean W. Mulvaney, MD, Consortium for Health and Military Performance, Military and Emergency Medicine, Uniformed Services University, 4301 Jones Bridge Road, Bethesda, MD 20814, U.S.A. E-mail: seanmulvaney@hotmail.com.

Submitted: November 9, 2009; Revision accepted: February 13, 2010  
DOI: 10.1111/j.1533-2500.2010.00373.x

**Key Words:** post-traumatic stress disorder, stellate ganglion block, anxiety, sympathetic

## INTRODUCTION

Post-traumatic stress disorder (PTSD) is a pathological anxiety condition that occurs when an individual experiences or witnesses severe trauma constituting a threat to his/her physical integrity or that of another person. The individual initially responds with intense fear, a sense of helplessness, or horror. Later he or she re-experiences the event, with resultant symptoms of numbness, avoidance, hypervigilance, or hyperarousal. These symptoms lead to clinically significant distress and/or functional impairment.<sup>1</sup>

The reported incidence of PTSD is increasing in military populations. The reasons for this increase are complex but can be linked to the nation's continued military engagements. The urgent need for effective and rapid treatment of PTSD was highlighted by a recent wide-ranging Department of Defense survey that was completed in 2008 and reported in December 2009. This survey of more than 28,000 service members showed that PTSD symptoms increased from 9% (never combat-deployed) to 22% (deployed three or more times) as the number of deployments increased. Of particular concern, when data from the 2008 survey were compared with a previous iteration administered in 2005, the rate of those meeting screening criteria for PTSD across the entire military force increased from 7% to 11%, with the greatest rate increases among Army soldiers and Marines.<sup>2</sup> In 2004, Hoge et al. found the incidence of PTSD symptoms among returning war veterans was 18%.<sup>3</sup> It can be expected that current figures are consistent with these findings, and may exceed them, as our military force remains continuously engaged overseas.

PTSD is a debilitating condition which urgently needs safe and effective therapies. However, as recently as 2007, an expert panel convened by the Institute of Medicine found that efficacy of most currently employed PTSD treatment modalities are low.<sup>4</sup> PTSD appears to be a complex and treatment-resistant condition whose treatment success rates appear to have improved little over the past decade despite considerable effort and research. The rates in the 2007 Institutes of Medicine study were equivalent to that described in 1995 by Kessler et al.<sup>5</sup>

Traditionally, medical approaches to PTSD have relied upon pharmacological agents with heavy utiliza-

tion of selective serotonin reuptake inhibitors (SSRIs) which affects the levels of serotonin in the brain. The challenge, according to a consensus statement from the Institute on Medicine, is that although these medications have relatively low rates of significant side-effects, only 50% to 60% of patients enjoy any appreciable reduction in symptoms. Further, SSRIs can take up to eight weeks to achieve a clinical response, and are associated with a high drop-out rate of 30% to 50%.<sup>6</sup> Other approaches include light therapy and exposure therapy, but the efficacy of each depends upon treatment duration and compliance.

Our case studies involve another unconventional approach to PTSD, which strives to reduce PTSD symptoms through changes in the sympathetic nervous system (SNS). Administered correctly, prazosin is an effective agent to reduce sympathetic tone. Prazosin, an alpha-1 adrenergic antagonist, acts by blocking the alpha-1 receptor, which is the main receptor of the SNS. Prazosin has been found to have significant success in the reduction or complete removal of post-traumatic nightmares among Vietnam veterans with combat-related PTSD.<sup>7</sup> Sympathetic blockade for the treatment of PTSD is not a new concept. In 2003, a published report demonstrated a reduction in PTSD-associated anxiety by clipping the sympathetic ganglia, via an endoscopic sympathetic block (ESB) at the second thoracic vertebra (T2).<sup>8</sup> Previously, Teleranta had reported successful treatment of severe anxiety and social phobias by the same approach.<sup>9</sup> Teleranta noted that social phobias and PTSD share some common features—especially symptoms associated with overactivity of the SNS, such as “heart racing”, hypervigilance, and avoidance of painful psychic situations.<sup>9</sup> Most recently, the first successful use of a stellate ganglion block (SGB) for the treatment of PTSD was reported in 2008.<sup>10</sup> Each of these advances motivated the authors to conduct a pilot study of SGB for the relief of PTSD symptoms among service members to quantify the benefit and duration of relief.

## METHODS

### Right C6 Cervical Sympathetic Chain Blockade

Once written consent was administered, a right-sided SGB was performed. An intravenous line was started with a 22G IV in the left hand. The patient was positioned comfortably in the supine position and prepped and draped in the sterile fashion. After radiographic confirmation of the right C6 transverse process, the skin

was anesthetized with 1 cc of 2% lidocaine. Using an anterior paratracheal approach, a 25-gauge Quincke needle was passed under fluoroscopic guidance until it contacted the transverse process of the C6 vertebra and then was pulled back 1 mm. Appropriate needle position was then confirmed by injection of 2 cc of iohexol (180 mg/mL) radio-opaque dye to monitor its spread. After negative aspiration, 7 cc of 0.5% ropivacaine was slowly injected to produce a sympathetic block. We monitored the patient's right hand temperature for 15 minutes following the anesthetic administration to confirm successful blockade of the cervical sympathetic ganglia as evidenced by an increase of at least 1.5°Celsius.<sup>11</sup> We also observed the patient for facial anhidrosis and Horner's syndrome (ie, enophthalmos, ptosis, swelling of the lower eyelid, miosis, and heterochromia) for further confirmation.

### PSYCHOMETRIC TESTING

The Post-traumatic Stress Disorder Checklist (PCL) is a 17-item psychometric test commonly used to screen for PTSD. It was developed based on PTSD criteria from the Diagnostic and Statistical Manual of Mental Disorders.<sup>1</sup> The PCL's initial validation<sup>12</sup> found that it was an effective brief screen for identifying PTSD, though the sample did not include patients experiencing combat-related PTSD. The PCL has since been validated for screening troops returning from combat to identify those with PTSD<sup>13</sup> as well as assessing symptom improvement as a result of treatment.<sup>14</sup> Different cutoff scores have been recommended for identifying PTSD, with ranges spanning 30 to 50. Forbes et al. (2001) concluded the optimal cutoff score for identifying combat related PTSD is a score of 50.<sup>14</sup> The most conservative cutoff score suggested that selecting a score between 30 and 34 would be an appropriate cutoff for more sensitive symptom surveillance.<sup>13</sup>

### CASE REPORTS

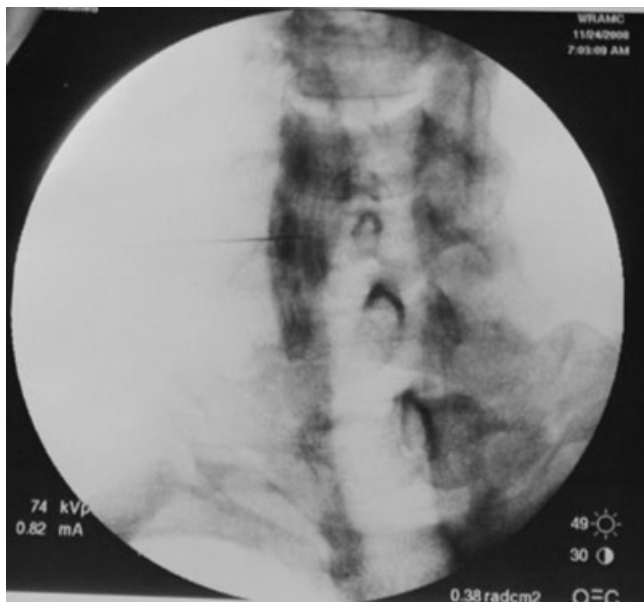
#### Case 1

The patient was a 46-year-old Hispanic male recently retired from the military. His PTSD symptoms commenced in the first Gulf War following a close-quarters combat event in an Iraqi-held bunker in which 10 enemy combatants were killed at close range and he was briefly rendered unconscious from an explosion. The patient was not visibly injured in the assault. Though he would go on to experience significant PTSD symptoms, he chose not to seek treatment while on active duty service

because of concerns that doing so would harm his career or negatively impact his security clearance.

At the time of the SGB, the patient had been in the care of a psychiatrist for over one year. His medications included sertraline, quetiapine, trazadone, venlafaxine, and zolpidem. Quetiapine was prescribed to control PTSD-related nightmares, and he was never diagnosed with any type of thought disorder or other psychotic condition. His initial pre-injection PCL score was 76 out of a maximum score of 85. He recounted that since his trigger event he could not recall a time when he slept for more than 2 to 3 hours. He reported waking three to four times a night with disturbing combat-related nightmares. He described having frequent flashbacks at seemingly random times, to include while driving. Further, he indicated that he would "re-live" the events in the bunker, to include feeling "the force of the blast on my skin." These symptoms had a tremendous negative impact on his quality of life. The patient indicated that pharmacologic treatment improved his symptoms somewhat, but he hoped for greater relief. He suffered adverse effects from the medications to include somnolence and adverse sexual effects. In the weeks prior to his SGB, the patient fell asleep while driving and damaged his car.

As part of the consent process the patient was informed that SGB was a novel therapy for his condition. He provided his consent and articulated that he believed his somnolence represented a much greater danger than an injection would. SGB with ropivacaine at the level of the sixth cervical vertebrae on the right side under fluoroscopic guidance was performed. The radio-opaque dye pattern was "V" shaped and consistent in appearance with a well-placed SGB (Figure 1). Five minutes after the placement of the SGB, the patient noted symptom improvement, spontaneously reporting he felt as if "a cloud had lifted" from his mind. He stated, "I haven't felt this good since high school". He rated that his global feelings of anxiety improved from a pre-SGB of 8 out of 10 (10 being the most anxiety he had ever experienced) to a 2 out of 10 following the SGB. He expressed a great deal of satisfaction with his initial symptomatic improvement. In the following two months, the patient was able to taper off all medications except for zolpidem QHS. He reported that for the first time since his symptoms started (18 years ago) he was able to sleep for 6 to 7 hours a night, and noted his nightmares diminished in both intensity and frequency. He articulated feeling "in control" again. Under the supervision of his psychiatrist, he discontinued



**Figure 1.** Case 1: stellate ganglion block 1—Fluoroscopic PA image.

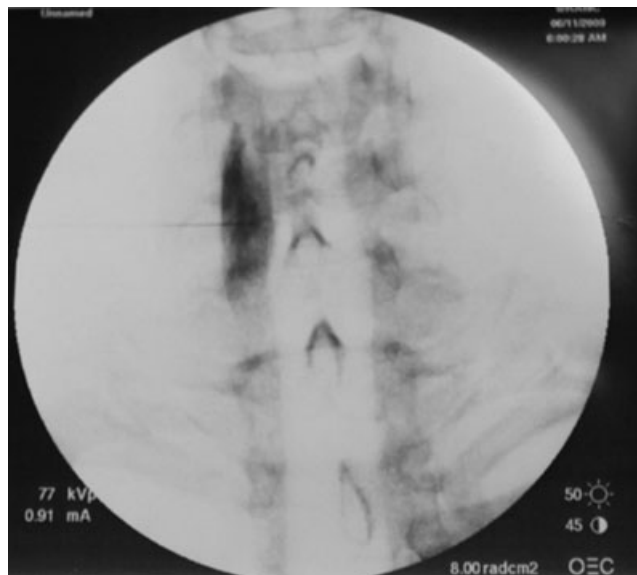
medications and noted feeling more alert and productive in his work.

The patient's symptoms remained in remission as measured by PCL scores and his subjective experience for three months, at which point his symptoms began to return in frequency and intensity. Seven months after the initial SGB, his PCL score had risen to 67. At this point he requested a second trial of SGB, which was performed (Figure 2). The post-treatment PCL score after his second SGB was 23, and he reported similar benefits to his first SGB. After 7 weeks his PCL score was 34 and his symptoms have held at that score for three more months.

Although the patient's PCL scores did increase from 25 up to 34 over 7 weeks, he continues to report that he has experienced significant symptomatic improvement. It is worth noting that his current score (34) falls in the range recommended by Bliese et al. for surveillance detection of PTSD, but far below that recommended by the National Center for PTSD. Regardless, his score represents a dramatic improvement when compared with his initial baseline PCL scores (76 and 67, respectively). It is also worth noting that the improved scores represent his symptomatology after discontinuing all psychotropic medications.

### Case 2

The second patient was a 36 year old white male active duty service member. His symptoms were triggered by



**Figure 2.** Case 1: stellate ganglion block 2—Fluoroscopic PA image.

events experienced in the Battle of Fallujah during Operation Iraqi Freedom. He was engaged in killing enemy combatants at close range and described being exposed to “hundreds” of civilian and combatant dead.

His symptoms included pronounced anxiety symptoms such as shortness of breath, heart palpitations, poor sleep, and nightmares. The patient's anxiety symptoms were in direct response to a triggering event, and do not appear to be related to a co-morbid diagnosis. He indicated that he would often “lock himself away” in a room within his house to avoid others while enduring his symptoms. He divorced 2 years after the onset of his symptoms and admits “he was not a pleasant person” during this time. He expressed a belief that his symptoms were causal factors in his marital breakdown and was in the care of a psychiatrist for 1 year before his SGB. His pharmacologic treatment included mirtazapine, sertraline, and zolpidem. Adverse effects of his medication included erectile dysfunction. His pre-SGB PCL score was 54.

The patient underwent SGB, per the methods section, with the radio-opaque dye showing a “V” shaped dye pattern consistent with good placement (Figure 3). Fifteen minutes after the block his skin temperature had risen 3°C indicating an appropriate sympathetic block. The patient's spontaneous comments following the block included the following: “I feel at peace,” “I'm just starting to be aware of how much anxiety I have been living with,” “my mind is not racing,” and “this is

remarkable.” His post- injection PCL score was 24 (with a minimum score of 17). During a recent follow-up seven months after his SGB, his PCL score remained consistent at 24. He has discontinued all medications. He reports feeling like himself, and no longer feels “like an unpleasant person.” His erectile dysfunction resolved when he discontinued medications. He is an enthusiastic supporter of SGB, and feels it has made a significant impact on his condition. He is relieved to no longer have the need to “lock himself away.”

Results of PCL testing for both cases are provided in Table 1.

### DISCUSSION

A potential reason for the similarity of reported effects after ESB at the thoracic ganglia (T2) and SGB may be that both ganglia have comparable sympathetic interventions (Figure 4). Many of the efferent sympathetic fibers from the thoracic ganglia pass through the stellate ganglion.<sup>15</sup> Additionally, the T2 ramus communicans is

a known connection between the upper thoracic ganglion and the stellate ganglion.<sup>16</sup>

Utilizing pseudorabies virus, Westerhaus and Loewy demonstrated how the stellate ganglion is connected to the hypothalamus and central nucleus of the amygdala as well as the insular cortex.<sup>17</sup> Utilizing functional magnetic resonance imaging (fMRI) Maihöfner and Forster demonstrated activation of the insular cortex during mechanical hyperesthesia (pain with light touch) associated with chronic regional pain syndrome.<sup>18</sup> Also utilizing fMRI, Liberzon and Martis demonstrated activation of the insular cortex in PTSD patients.<sup>19</sup> Thus, the fMRI appears to demonstrate the potential role of the insular cortex in PTSD.

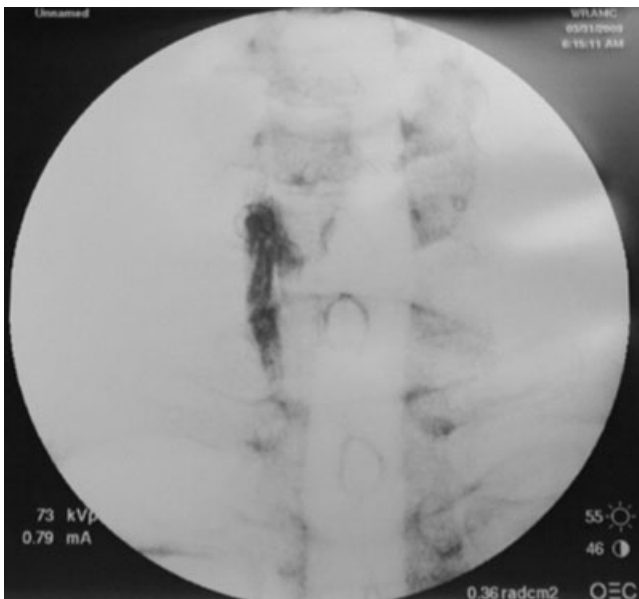


Figure 3. Case 2: stellate ganglion block—Fluoroscopic PA image.

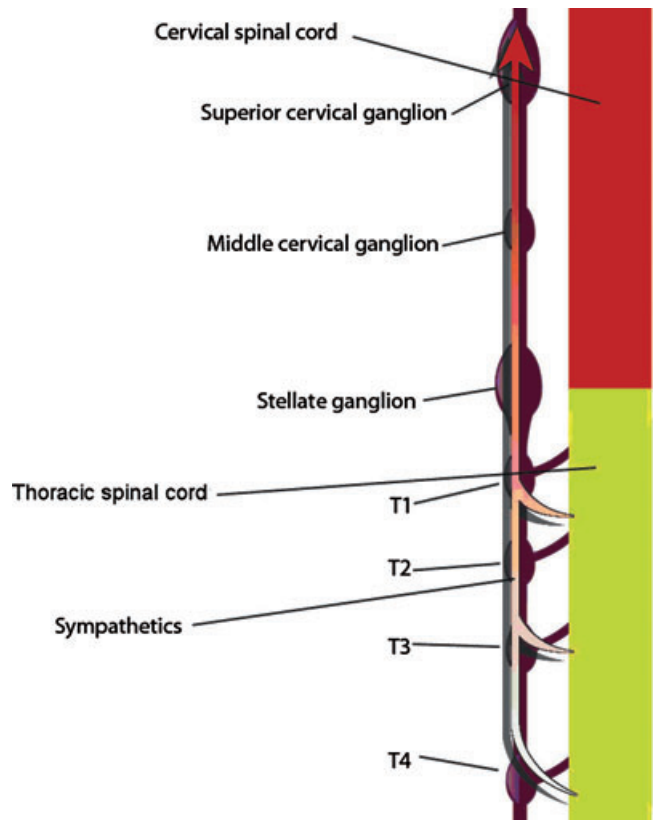


Figure 4. Sympathetic fibers originate from the spinal cord at the thoracic level and enter the sympathetic chain that leads up to the brain. Thus, a T2 block is neurologically similar to a C6 or C7 block of the stellate ganglion.

Table 1. Longitudinal Post-Traumatic Stress Disorder Checklist Scores for Both Cases

Patient	Pre	Post	3 Weeks	4 Weeks	5 Weeks	7 Weeks	24 Weeks	28 Weeks
1	76	26					32	
1 (second treatment)	67	25	29	30	31	34		
2	54	24						24

Nerve growth factor (NGF), which is involved in a variety of signaling events such as cell differentiation and survival, growth cessation, and apoptosis of neurons,<sup>20</sup> may help explain the symptom relief our patients have experienced following SGB. Concentrations of NGF are known to increase with chronic stress<sup>21</sup> and NGF is also known to elevate immediately prior to the first parachute jump.<sup>22</sup>

The NGF increase leads to retrograde transport from the intracerebral site to the stellate ganglion and eventually causes sprouting (new nerve growth) at the nerve terminals.<sup>23,24</sup> Sprouting, in turn, leads to increased norepinephrine (NE) output<sup>25</sup> detected in elevated urine levels among those with PTSD,<sup>26</sup> possibly contributing to the development of the pathologic states described. Although there may be several reasons for elevated NE, an increased level of NE could contribute to the anxiety symptoms associated with PTSD. Local anesthetic injection next to a sympathetic ganglion leads to the reduction of NGF, and the reversal of NGF increases its “downstream” effects.<sup>27,28</sup> Lipov and colleagues hypothesize that after a SGB the concentration of NGF decreases, leading to reduction in NE and deactivation of the intracerebral pathologic states.<sup>29</sup>

## CONCLUSION

Unlike conventional treatments for PTSD, SGB appeared to have provided results almost immediately. Our series of two patients suggests a potentially effective and readily accessible approach for PTSD treatments. We believe that further investigation of this intervention is warranted and may provide alternatives and/or complements to current psychological and pharmacological treatments for PTSD, an increasingly prevalent condition in military populations. In addition to the clinical benefit, if SGB proves efficacious in larger trials, the intervention may reduce the overall cost of care for PTSD by minimizing the use of poly-pharmacy.

## REFERENCES

1. American Psychiatric Association. *Diagnostic and Statistical Manual of Mental Disorders*. 4th ed. Washington, DC: American Psychiatric Association; 1994.
2. Bray RM, Pemberton MR, Hourani LL, et al. *2008 Department of Defense Survey of Health Related Behaviors among Active Duty Military Personnel*. Research Triangle Park, NC: Research Triangle Institute; 2009.
3. Hoge CW, Castro CA, Messer SC, McGurk D, Cotting DI, Koffman RL. Combat duty in Iraq and

Afghanistan, mental health problems, and barriers to care. *N Engl J Med*. 2004;351:13–22.

4. Institute of Medicine. *Treatment of Posttraumatic Stress Disorder: An Assessment of the Evidence*. Washington, DC: The National Academies Press; 2007.

5. Kessler RC, Sonnega A, Bromet E, Hughes M, Nelson CB. Posttraumatic stress disorder in the national co-morbidity survey. *Arch Gen Psychiatry*. 1995;52:1048–1060.

6. Institute of Medicine Treatment of PTSD. *An Assessment of the Evidence (Report Brief)*. Washington, DC: The National Academies Press; 2008.

7. Raskind MA, Peskind ER, Kanter ED, et al. Reduction of nightmares and other PTSD symptoms in combat veterans by prazosin: a placebo-controlled study. *Am J Psychiatry*. 2003;160:371–373.

8. Telaranta T. Psychoneurological applications of endoscopic sympathetic blocks (ESB) [invited lecture]. *Clin Auton Res*. 2003;13:1120–1121.

9. Telaranta T. Treatment of social phobia by endoscopic thoracic sympathectomy. *Eur J Surg Suppl*. 1998;580:27–32.

10. Lipov EG, Joshi JR, Lipov SG, Sanders SE, Siroko MK. Cervical sympathetic blockade in a patient with post-traumatic stress disorder: a case report. *Ann Clin Psychiatry*. 2008;20:227–228.

11. Hogan QH, Taylor ML, Goldstein M, Stevens R, Kettler R. Success rates in producing sympathetic blockade by paratracheal injection. *Clin J Pain*. 1994;10:139–145.

12. Blanchard EB, Jones-Alexander J, Buckley TC, Forneris CA. Psychometric properties of the PTSD Checklist (PCL). *Behav Res Ther*. 1996;34:669–673.

13. Bliese PD, Wright KM, Adler AB, Cabrera O, Castro CA, Hoge CW. Validating the Primary Care Posttraumatic Stress Disorder Screen and the Posttraumatic Stress Disorder Checklist with soldiers returning from combat. *J Consult Clin Psychol*. 2008;76:272–281.

14. Forbes D, Creamer M, Biddle D. The validity of the PTSD checklist as a measure of symptomatic change in combat-related PTSD. *Behav Res Ther*. 2001;39:977–986.

15. Uchida K, Tateda T, Hino H. Novel mechanism of action hypothesized for stellate ganglion block related to melatonin. *Med Hypotheses*. 2002;59:446–449.

16. Chung IH, Oh CS, Koh KS, Kim HJ, Paik HC, Lee DY. Anatomic variations of the T2 nerve root (including the nerve of Kuntz) and their implications for sympathectomy. *J Thorac Cardiovasc Surg*. 2002;123:498–501.

17. Westerhaus MJ, Loewy AD. Central representation of the sympathetic nervous system in the cerebral cortex. *Brain Res*. 2001;903:117–127.

18. Maihöfner C, Forster C, Birklein F, Neundörfer B, Handwerker H. Brain processing during mechanical hyperalgesia in complex regional pain syndrome: a functional MRI study. *Pain*. 2005;114:93–103.

19. Liberzon I, Martis B. Neuroimaging studies of emotional responses in PTSD. Psychobiology of posttraumatic stress disorder: a decade of progress. *Ann N Y Acad Sci.* 2006;1071:87–109.
20. Snider WD. Functions of the neurotrophins during nervous system development: what the knockouts are teaching us. *Cell.* 1994;77:627–638.
21. Smith MA. Hippocampal vulnerability to stress and aging: possible role of neurotrophic factors. *Behav Brain Res.* 1996;78:25–36.
22. Alleva E, Petrucci S, Cirulli F, Aloe L. NGF regulatory role in stress and coping of rodents and humans. *Pharmacol Biochem Behav.* 1996;54:65–72.
23. Johnson EM Jr, Taniuchi M, Clark HB, et al. Demonstration of the retrograde transport of nerve growth factor receptor in the peripheral and central nervous system. *J Neurosci.* 1987;7:923–929.
24. Chen PS, Chen LS, Cao JM, Sharifi B, Karagueuzian HS, Fishbein MC. Sympathetic nerve sprouting, electrical remodeling and the mechanisms of sudden cardiac death. *Cardiovasc Res.* 2001;50:409–416.
25. Isaacson LG, Billieu SC. Increased perivascular norepinephrine following intracerebroventricular infusion of NGF into adult rats. *Exp Neurol.* 1996;139:54–60.
26. Kosten TR, Mason JW, Giller EL, Ostroff RB. Sustained urinary norepinephrine and epinephrine elevation in post-traumatic stress disorder. *Psychoneuroendocrinology.* 1987;12:13–20.
27. Gatzinsky KP, Thrasivoulou C, Campioni-Noack M. The role of NGF uptake in selective vulnerability to cell death in ageing sympathetic neurons. *Eur J Neurosci.* 2004;20:2848–2856.
28. Takatori M, Kuroda Y, Hirose M. Local anesthetics suppress nerve growth factor-mediated neurite outgrowth by inhibition of tyrosine kinase activity of TrkA. *Anesth Analg.* 2006;102:462–467.
29. Lipov E, Joshi J, Sanders S, Slavin K. A unifying theory linking the prolonged efficacy of the stellate ganglion block for the treatment of chronic regional pain syndrome (CRPS), hot flashes, and posttraumatic stress disorder (PTSD). *Med Hypotheses.* 2009;72:657–661.